

Curvature Analysis of Mandibular Condyle by Multidetector Computed Tomography

VISHWANATH T THIMMAIAH, NAGRAJMURTHY

ABSTRACT

Introduction: Condylar surface of mandible has varied curved shapes and its assessment is important clinically for better management of Temporomandibular (TMJ) pathologies. Multidetector Computed Tomography (MDCT) is the modality of choice for curvature analysis of mandibular condyle.

Aim: To assess the curvature types of mandibular condyle by MDCT. Symmetry of condylar curvature was also analysed in the present study.

Materials and Methods: This retrospective descriptive analysis of bilateral TMJ was done in 500 adult cases. Curvature analysis of bilateral mandibular condyles was done by MDCT in coronal reformatted images.

Statistical Analysis: Statistical Analysis was done using SPSS version 20 for frequency of each curvature type and their symmetry.

Results: Type D was most common (bilateral TMJ considered) with 335 cases (33.50%) among the total number (n=1000) of TMJ studies. On right TMJ studies (n=500) Type D was most common with 172 cases (34.40%) and on left TMJ studies (n=500) type D was again most common with 163 cases (32.60%). Of the total 257 cases that showed symmetry, Type D was most common with 90 cases (35%) and also to be the most common type seen in males with 50 cases (30.8 %) and females with 40 cases (42%).

Conclusion: Curvature analysis is done to know the morphological types of mandibular condyles. Type D is most common type of curvature seen and is symmetrical. Condylar curvature is an important determinant factor for various TMJ pathologies with MDCT offering an excellent non invasive imaging modality for curvature analysis.

Keywords: Articular disc, Symmetry, Temporomandibular joint

INTRODUCTION

TMJ is a complex ginglymo-diarthroidal joint consisting of condylar process of mandible, glenoid fossa of squamous temporal bone and articular disc which is enclosed in a fibrous capsule and stabilized by Temporomandibular and sphenomandibular ligaments [1]. TMJ is an important and unique joint in the body that, besides functioning as a joint, it also acts as a site for regional adaptive growth [2]. Condylar process of human condyle is unique with its ability to remodel and giving rise to variety of morphological types [3]. Condylar morphology is very important for TMJ to carry out various movements like opening, closing, lateral or translational movements of the jaw. Condylar morphology varies with age, gender, laterality, facial types and functional load over the joint [4]. Curvature analysis of TMJ is very essential, so as to differentiate a normal variant from that of abnormal variant which helps in better management of various TM abnormalities

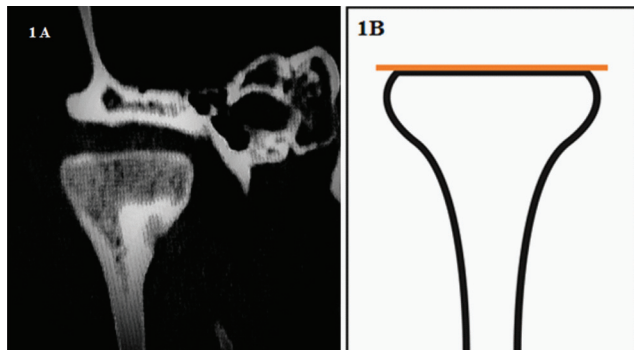
[5]. MDCT provides a most effective non invasive imaging modality for assessment of curvature of bilateral mandibular condyles because of its faster scanning ability, high resolution imaging and excellent multiplanar reconstructions.

MATERIALS AND METHODS

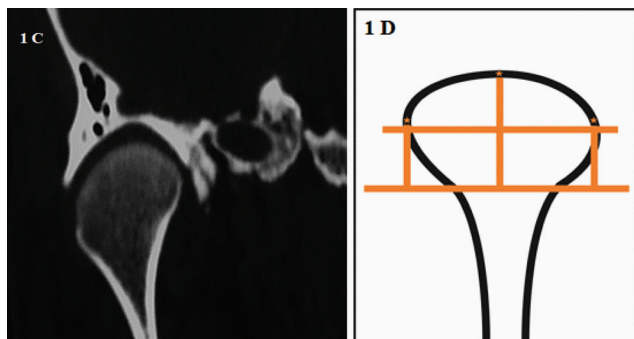
A retrospective descriptive study was undertaken in the Department of Radiology, JSS Medical College and Hospital, Mysuru, Karnataka, India over a period of three months starting from April 2016 till June 2016. A total of 523 cases underwent MDCT scan involving both TMJ, out of which 500 cases satisfying inclusion criteria were included in the study. All patients above 18 years of age of both sexes who underwent MDCT scans involving bilateral TMJ were included in the study. Post traumatic/inflammatory/neoplastic lesions with erosion/distortion of curvature of either or both mandibular condyles. Axial images involving bilateral TMJ were acquired with Philips Ingenuity core 128 slice MDCT

(Netherlands). Patient is positioned supine with head first and axial sections were acquired with helical type of scan, by fixing the tube current at 120kVp and 350 mA/sec. High resolution images were obtained with scan parameters of collimation 64 x 0.625, Pitch of 0.39, FOV of 160mm, filter at Y-sharp (YC), slice thickness of 1mm, window centering at 200 and window width of 2000. Multiplanar reconstruction was done from axial images in a dedicated work station to obtain coronal reformatted images without any loss of volume data. Images were stored in hospital PACS system and the images were retrieved from hospital data base system. Reporting was done by a single radiologist by visual and analytical methods for condylar curvature in coronal reformatted image and their symmetry was compared. All the images were examined in coronal reformatted plane. Curvature analysis was done by both visual and analytical methods and categorised into five types based on the following methodology. A horizontal line was drawn at the base of curvature. Highest peak point was marked on the curvature of mandibular condyle and another vertical line drawn connecting the highest point and the horizontal line. Flat surface (Type A), [Table/Fig-1a,b] did not show any curvature or highest peak point, Round surface (Type B), [Table/Fig-1c,d] has uniform curvature and showed three peak points with longer vertical line, Angled surface (Type C), [Table/Fig-1e,f] has uneven curvature with a single highest peak point, Convex surface (Type D), [Table/Fig-1g,h]

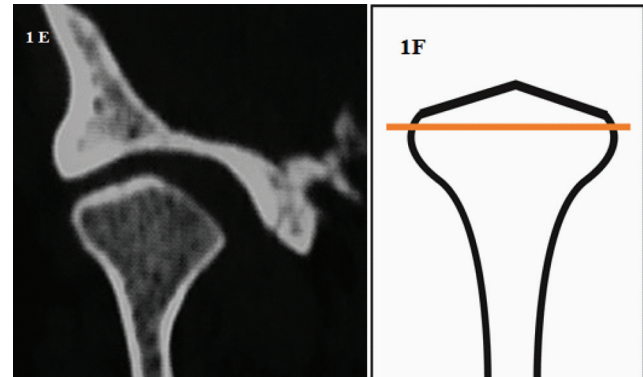
has a uniform curvature with single highest point and short vertical line and concave shaped (Type E), [Table/Fig-1i,j] has inverted curvature to varying depths.



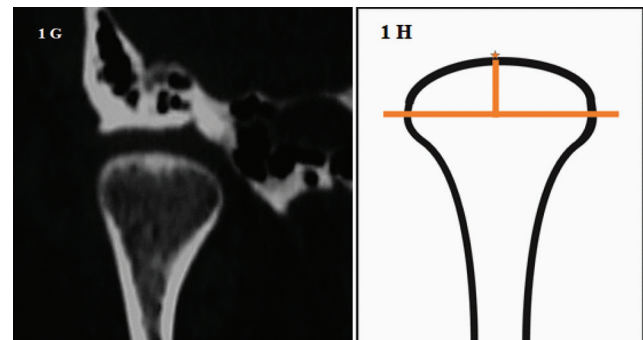
[Table/Fig-1a-b]: Coronal reformatted CT and graphical image showing flat curvature (Type A).



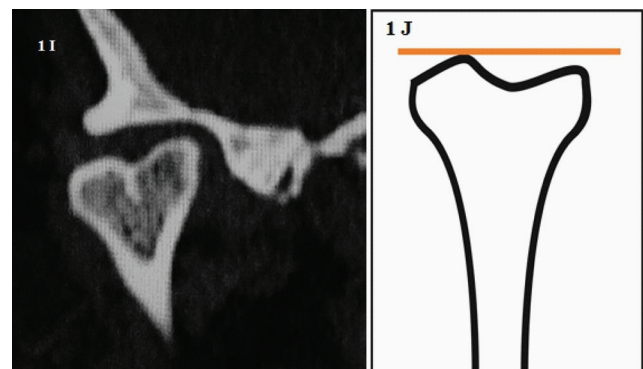
[Table/Fig-1c-d]: Type B with round curvature on coronal CT and graphical image.



[Table/Fig-1e-f]: Angle shaped curvature on coronal CT and graphical image (Type C).



[Table/Fig-1g-h]: Coronal CT and graphical image showing convex curvature (Type D).



[Table/Fig-1i-j]: Mandibular condyle showing concave shaped curvature on CT and graphical image (Type E).

STATISTICAL ANALYSIS

All the data was entered in Microsoft excel sheet for analysis. Categorical variables were reported as proportions. Analysis was done using Microsoft Excel 2013, SPSS version 20. Frequency of individual curvature type was calculated and symmetry among each type was recorded.

RESULTS

Out of 500 MDCT studies involving bilateral TMJ, age group in our study ranged from 18 to 83 years. The different curvature types involving each side are shown in [Table/Fig-2]. Type D was most common (both TMJ considered) with 335 cases (33.50%) among the total number (n=1000) of TMJ studies and also the most commonest type in right TMJ with 172 cases (34.4%)(n=500) and in left TMJ with 163 cases (32.06%)(n=500). A total of 257 cases among the total 500 cases showed symmetrical condyles. Different curvature types showing symmetry are shown in [Table/Fig-3]. Distribution of

Curvature Types of Condylar Process	Right	Percentage (%)	Left	Percentage (%)	Total	
Type- A (Flat)	111	22.20%	90	18.00%	201	20.1%
Type- B (Round)	65	13.00%	76	15.20%	141	14.1%
Type- C (Angled)	120	24.00%	137	27.40%	257	25.70%
Type- D (Convex)	172	34.40%	163	32.60%	335	33.5%
Type- E (Concave)	32	06.40%	34	06.80%	66	6.6%
Total	500	100%	500	100%	1000	100%

[Table/Fig-2]: *Curvature types of bilateral condylar process of mandible with frequency and percentages.

Curvature Types of Condylar Process	Total Number Cases (n=257)	Percentage %
Type- A	60	23.34%
Type- B	41	15.95%
Type- C	48	18.67%
Type- D	90	35.01%
Type- E	18	7.00%
Total	257	100%

[Table/Fig-3]: *Curvature types of mandibular condyles showing symmetry.

symmetrical condyles among different age groups is shown in [Table/Fig-4]. Type D was most common in most of the age groups ranging from 21 to 70 years .Among the total 257 symmetrical cases, 162 (63%) were males and 95(37%) females Type D was most common in both sexes showing symmetry with 30.8% in males and 42.1% [Table/Fig-5]. Asymmetrical cases were seen most commonly in < 20 years and >80 year age groups.

DISCUSSION

Condylar morphology varies in shape and size among different population depending upon their age, gender, laterality, facial type and occlusal force. Mandibular condyle is also one of the main site for facial growth that occurs in upward and backward direction contributing to its shape obtained [6]. Normally condylar head should have convex surface

Age groups (in years)	Type A		Type B		Type C		Type D		Type E		Total
	Number of Cases	Percentage (%)	Number of Cases	Percentage (%)	Number of Cases	Percentage (%)	Number of Cases	Percentage (%)	Number of Cases	Percentage (%)	
<20	7	16.6%	14	33.33%	9	21.42%	9	21.42%	3	7.14%	42.00
21-30	11	27.50%	8	20.00%	7	17.50%	14	35.00%	0	0.00%	40.00
31-40	10	23.25%	3	6.97%	8	18.60%	20	46.51%	2	4.65%	43.00
41-50	6	16.66%	6	16.66%	4	11.11%	12	33.33%	8	22.22%	36.00
51-60	8	16.66%	8	16.66%	9	18.75%	21	43.75%	2	4.16%	48.00
61-70	6	23.07%	2	7.69%	5	19.23%	10	38.46%	3	11.53%	26.00
71-80	10	62.50%	0	0.00%	2	12.50%	4	25.00%	0	0.00%	16.00
>81	2	33.33%	0	0.00%	4	66.66%	0	0.00%	0	0.00%	6.00
Total	60		41		48		90		18		257.00

[Table/Fig-4]: Symmetry of curvature types of mandibular condyle among different age groups.

Sex	Type A		Type B		Type C		Type D		Type E		Total
	Number of Cases	Percentage (%)	Number of Cases	Percentage (%)	Number of Cases	Percentage (%)	Number of Cases	Percentage (%)	Number of Cases	Percentage (%)	
Male	38	23.45%	25	15.43%	39	24.07%	50	30.86%	10	6.17%	162
Female	21	22.10%	16	16.84%	10	10.52%	40	42.10%	8	8.42%	95
Total	59		41		49		90		18		257

[Table/Fig-5]: *Symmetry of curvature types of mandibular condyle among males and females.

throughout and symmetrical bilaterally to carry out smooth functioning of TMJ. It measures 15 to 20 mm side to side and 8 to 10 mm from anterior to posterior [7]. Morphologic changes of mandibular condyle can occur due to bone remodeling, developmental variations, trauma, endocrine disturbances, hormonal abnormality, various disease pathologies and following radiation therapy. The different morphologies and the curvature shapes play an important role clinically so as to understand the pathophysiology of joint diseases and for their appropriate management. Various studies have been carried out to study condylar morphology and its curvature, Yale et al., being the first one. In his study based on the superior view of condyle he described four types: convex (58.3%), flat (52.5%), angled (11.6%), rounded (3.1%) and unclassified (1.9%) with increasing age, there was increase in flat type and decrease in convex type of condylar morphology [8]. However, in our study there was not much change in the type of curvature with increasing age. He also stated that flat type is more common in females compared to convex type in males and overall convex type being common in all age groups [8]. In our study also, convex surface (Type D) was most common in all age groups and symmetrical type D being common in both males and females. In another study by Cimen et al., the following percentages were seen, flat (17.4%), convex (33.7%), angled (37.8%), round (9.3%) and unclassified in (1.8%) [9]. According to Emmering et al., bilateral asymmetry (24%) in mandibular condyles constituted, Flat type on one side and convex type on the other side [10]. However, a greater proportion of cases (51.4%) in our study showed symmetry of mandibular condyles and asymmetry was noticed in the rest 48.6% cases.

Many radiological methods are available for assessing condylar morphology like CT-scan [3], cone beam CT [11], OPG, lateral cephalogram and MRI. First study on TMJ using CT was done by Christiansen et al., in coronal plane to demonstrate condylar morphology. Flat type was seen in 34%, convex in 43%, angled in 19% and rounded in 9% of cases [12] in his study. Later Raustia & Pyhtinen standardised condyle shapes on coronal CT plane and divided into A1 shape (rounded or slightly convex), A2 (extensively flat - straight), A3 (peak shape - inverted V) and A4 (other shapes) [13]. Ueda et al., in their study of condylar morphology using high resolution CT, classified them as flat, round, convex, concave and angled. Most common variant was convex type followed by angled, concave and round [14]. In our study we used 128 slice high resolution MDCT for curvature analysis of mandibular condyle and convex curvature (Type D) being most common type followed by flat surface (Type A).

Well balanced position of condylar process and proper morphological adaptation to glenoid fossa is essential for coordinated masticator functioning of TMJ. Temporomandibular joint derangements are common when

this proper morphological or curvature adaptation is lost [15]. Curvature analyses of mandibular condyle are very informative for analysis of various biomechanical abnormalities involving TMJ. Curvature of mandibular condyle is depicted effectively by CT and may be used as an effective non-invasive imaging tool for condyle morphometric analysis. Multiplanar reformation with MDCT has made the curvature analysis of bilateral mandibular condyles very easy in all planes compared to other imaging or non imaging modalities available for curvature analysis. Although, it has risk of radiation, MDCT can be used as a very useful imaging modality to assess condylar morphology and to evaluate various biomechanical abnormalities that affect TMJ like abnormality in elevation, depression, translational and rotational movements of jaw.

LIMITATIONS

Computer based graphic condyle models were not used in our study for curvature analysis.

CONCLUSION

Curvature analysis is done to know the morphological types of mandibular condyles. Type D (convex curvature) is most common type of curvature seen and is often symmetrical. Condylar curvature is an important determinant factor for various TMJ pathologies with MDCT offering an excellent noninvasive imaging modality for curvature analysis. MDCT analysis of curvature is easy and provides effective non-invasive imaging tool for in vivo assessment of condylar morphology.

REFERENCES

- [1] Durgha K. Condylar morphology- a review. IOSR-Journal of Dental and Medical Sciences. 2014;13(7):57-59.
- [2] Prabhat KC, Kumar Verma S, Maheshwari S, Ahmad I, Tariq M. Computed tomography evaluation of craniomandibular articulation in class ii division 1 malocclusion and class i normal occlusion subjects in North Indian population. ISRN Dentistry. 2012;2012:312031.
- [3] Katsavrias EG and Halazonetis DJ. Condyle and fossa shape in Class II and Class III skeletal patterns: A morphometric tomographic study. Am J Orthod & Dentofacial Orthop. 2005;128:337-46.
- [4] Saccucci M, D'Attilio M, Rodolfino D, Festa F, Polimeni A, Tecco S. Condylar volume and condylar area in class I, class II and class III young adult subjects. Head Face Med. 2012;8:34.
- [5] Hegde S, Praveen BN, Shetty SR. Morphological and radiological variations of mandibular condyles in health and diseases: a systematic review. Dentistry. 2013; 3:1.
- [6] Mathew AL, Sholapurkar AA, and Pai KM. Condylar changes and its association with age, TMD, and dentition status: a cross-sectional study. International Journal of Dentistry. 2011;7.
- [7] Standring S. Gray's anatomy 39th edition. The Anatomical Basis of Clinical Practice, Elsevier Ltd. 2005. pages:519- 30.
- [8] Yale SH, Rosenberg HM, Ceballos M, Haupt-Fuehrer JD. Laminagraphic cephalometry in the analysis of mandibular condyle morphology. A preliminary report. Oral Surg Oral Med Oral Path. 1961;14:793-805.

- [9] Cimen M, Isik AO and Gedik R. A radiological method on the classification of human mandibular condyles. *Okajimas Folia Anat Jpn.* 1999;76(5):263-72.
- [10] Emmering TE. A new approach to the analysis of the functional surfaces of the temporomandibular joint. *Oral Surg.* 1967;23:603-09.
- [11] Kurusu A, Horiuchi M, Soma K. Relationship between occlusal force and mandibular condyle morphology evaluated by limited cone-beam computed tomography. *Angle Orthod.* 2009;79(6):1063-69.
- [12] Christiansen EL, Chan TT, Thompson JR, Hasso AN, Hinshaw DB Jr, Kopp S. Computed tomography of the normal temporomandibular joint. *Scand J Dent Res.* 1987;95(6):499-509.
- [13] Raustia AM, Pyhtinen J. Morphology of the condyles and mandibular fossa as seen by computed tomography. *J Prosthet Dent.* 1990;63(1):77-82.
- [14] Ueda M, Yonetsu K, Ohki M, Yamada T, Kitamori H, Nakamura T. Curvature analysis of the mandibular condyle. *Dentomaxillofac Radiol.* 2003;32(2):87-92.
- [15] Poikela A, Pirttiniemi P, Kantomaa T. Location of the glenoid fossa after a period of unilateral masticatory function in young rabbits. *Eur J Orthod.* 2000;22(2):105-12.

AUTHOR(S):

1. Dr. Vishwanath T Thimmaiah
2. Dr. Nagrajmurthy

PARTICULARS OF CONTRIBUTORS:

1. Associate Professor, Department of Radiology, JSS Medical College and Hospital, Mysuru, Karnataka, India.
2. Professor, Department of Radiology, JSS Medical College and Hospital, Mysuru, Karnataka, India.

NAME, ADDRESS, E-MAIL ID OF THE CORRESPONDING AUTHOR:

Dr. Vishwanath T Thimmaiah,
#15, Block No 8, JSS Layout 1st Stage,
Mysuru, Karnataka-570019, India.
E-mail: vishurad@gmail.com

FINANCIAL OR OTHER COMPETING INTERESTS:

None.

Date of Online Ahead of Print: **Feb 17, 2017**

Date of Publishing: **Jul 01, 2017**